



**CardinalHealth**

*Essential to care™*

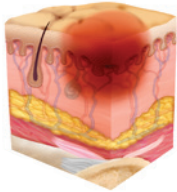
POCKET GUIDE:

# **Guidelines for staging of pressure injuries**

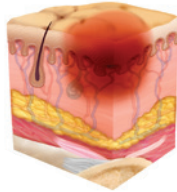
# WHAT IS A PRESSURE INJURY?

A pressure injury is localized damage to the skin and underlying soft tissue usually over a bony prominence or related to a medical or other device. The injury can present as intact skin or an open ulcer and may be painful. The injury occurs as a result of intense and/or prolonged pressure or pressure in combination with shear. The tolerance of soft tissue for pressure and shear may also be affected by microclimate, nutrition, perfusion, co-morbidities and condition of the soft tissue.

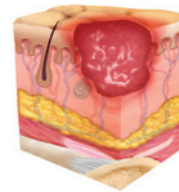
STAGE 1



STAGE 1 WITH EDEMA



STAGE 2



## STAGE 1 PRESSURE INJURY:

### Non-blanchable erythema of intact skin

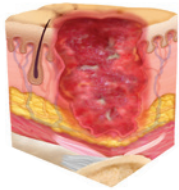
Intact skin with a localized area of non-blanchable erythema, which may appear differently in darkly pigmented skin. Presence of blanchable erythema or changes in sensation, temperature or firmness may precede visual changes. Color changes do not include purple or maroon discoloration; these may indicate deep tissue pressure injury.

## STAGE 2 PRESSURE INJURY:

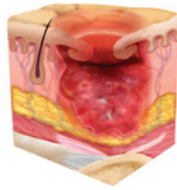
### Partial-thickness skin loss with exposed dermis

Partial-thickness loss of skin with exposed dermis. The wound bed is viable, pink or red, moist, and may also present as an intact or ruptured serum-filled blister. Adipose (fat) is not visible and deeper tissues are not visible. Granulation tissue, slough and eschar are not present. These injuries commonly result from adverse microclimate and shear in the skin over the pelvis and shear in the heel. This stage should not be used to describe moisture associated skin damage (MASD) including incontinence associated dermatitis (IAD), intertriginous dermatitis (ITD), medical adhesive related skin injury (MARS), or traumatic wounds (skin tears, burns, abrasions).

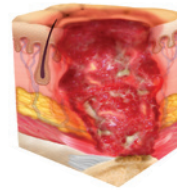
### STAGE 3



### STAGE 3 WITH EPIBOLE



### STAGE 4



## **STAGE 3 PRESSURE INJURY:**

### **Full-thickness skin loss**

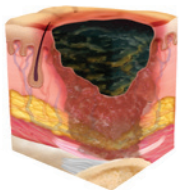
Full-thickness loss of skin, in which adipose (fat) is visible in the ulcer and granulation tissue and epibole (rolled wound edges) often are present. Slough and/or eschar may be visible. The depth of tissue damage varies by anatomical location; areas of significant adiposity can develop deep wounds. Undermining and tunneling may occur. Fascia, muscle, tendon, ligament, cartilage and/or bone are not exposed. If slough or eschar obscures the extent of tissue loss, this is an Unstageable Pressure Injury.

## **STAGE 4 PRESSURE INJURY:**

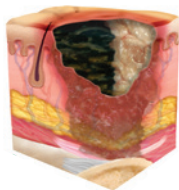### **Full-thickness skin and tissue loss**

Full-thickness skin and tissue loss with exposed or directly palpable fascia, muscle, tendon, ligament, cartilage or bone in the ulcer. Slough and/or eschar may be visible. Epibole (rolled edges), undermining and/or tunneling often occur. Depth varies by anatomical location. If slough or eschar obscures the extent of tissue loss, this is an Unstageable Pressure Injury.

### UNSTAGEABLE WITH DARK ESCHAR



### UNSTAGEABLE WITH SLOUGH AND ESCHAR

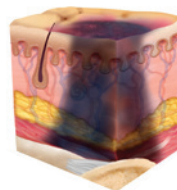


## UNSTAGEABLE PRESSURE INJURY:

### Obscured full-thickness skin and tissue loss

Full-thickness skin and tissue loss in which the extent of tissue damage within the ulcer cannot be confirmed because it is obscured by slough or eschar. If slough or eschar is removed, a Stage 3 or Stage 4 pressure injury will be revealed. Stable eschar (i.e., dry, adherent, intact without erythema or fluctuance) on the heel or ischemic limb should not be softened or removed.

### DTI



## DEEP TISSUE PRESSURE INJURY:

### Persistent non-blanchable deep red, maroon or purple discoloration

Intact or non-intact skin with localized area of persistent non-blanchable deep red, maroon, purple discoloration or epidermal separation revealing a dark wound bed or blood filled blister. Pain and temperature change often precede skin color changes. Discoloration may appear differently in darkly pigmented skin. This injury results from intense and/or prolonged pressure and shear forces at the bone-muscle interface. The wound may evolve rapidly to reveal the actual extent of tissue injury, or may resolve without tissue loss. If necrotic tissue, subcutaneous tissue, granulation tissue, fascia, muscle or other underlying structures are visible, this indicates a full thickness pressure injury (Unstageable, Stage 3 or Stage 4). Do not use DTPI to describe vascular, traumatic, neuropathic or dermatologic conditions.

### *Additional pressure injury definitions*

## **MEDICAL DEVICE RELATED PRESSURE INJURY:**

### **This describes an etiology.**

Medical device related pressure injuries result from the use of devices designed and applied for diagnostic or therapeutic purposes. The resultant pressure injury generally conforms to the pattern or shape of the device. The injury should be staged using the staging system.

## **MUCOSAL MEMBRANE PRESSURE INJURY:**

Mucosal membrane pressure injury is found on mucous membranes with a history of a medical device in use at the location of the injury. Due to the anatomy of the tissue, these ulcers cannot be staged.

# **WOUND ASSESSMENT CHECKLIST**

- Location
- Size
- Dressing used
- Drainage (amount/color/odor)
- Undermining/tunneling
- Stage
- Pressure redistribution
- Nutritional assessment
- Viable tissue in wound



Source: <http://www.npuap.org/resources/educational-and-clinical-resources/npuap-pressure-injury-stages/>

© 2018 Cardinal Health. All Rights Reserved. CARDINAL HEALTH, the Cardinal Health LOGO and ESSENTIAL TO CARE are trademarks or registered trademarks of Cardinal Health. All other marks are the property of their respective owners. Lit. no. 2SP18-79776 (05/2018)